

# Large-bore cricothyroidotomy devices

Bhavesh Patel MB BS FRCA  
Christopher Frerk MB ChB FRCA

Cricothyroidotomy (cricothyrotomy) is the creation of an opening in the space between the anterior inferior border of the thyroid cartilage and the anterior superior border of the cricoid cartilage, to gain access to the airway below the glottis.<sup>1</sup>

Indications for cricothyroidotomy are:

- (i) anticipated difficult airway: elective prophylactic cricothyroidotomy;
- (ii) elective provision of oxygenation ( $\pm$  ventilation) by subglottic route;
- (iii) 'Can't intubate can't ventilate' (CICV) scenario: emergency oxygenation ( $\pm$  ventilation).

There is confusion over nomenclature of cricothyroidotomy techniques and equipment. It is useful to classify devices according to internal diameter (ID).

- (i) Small cannula devices (2–3 mm ID) include the VBM Ravussin 13 G needle. The use of 14–16 G i.v. cannulae is frequently described, but this use is unlicensed and should be avoided.
- (ii) Large-bore devices (4 mm or larger ID) are designed to provide emergency oxygenation *and ventilation* through the cricothyroid membrane. Kits are manufactured by Portex, Cook, and VBM (Table 1 and Fig. 1).
- (iii) Surgical cricothyroidotomy for insertion of 6 mm (or greater) ID tracheal or tracheostomy tubes.

Small cannula techniques require a high-pressure oxygen source such as the Sanders injector or VBM Manujet to overcome the narrow resistance. Some degree of upper airway patency is essential to facilitate exhalation.

Since surgical airway techniques are less familiar to anaesthetists, they are often understandably reluctant to use them. This article focuses on large-bore emergency cricothyroidotomy

devices which enable ventilation with standard anaesthesia breathing systems.

## Anatomy

The cricothyroid membrane is composed mainly of yellow elastic tissue. It is on average 8 mm deep to the skin, 9 mm high, and 30 mm wide, and connects the thyroid cartilage superiorly and cricoid cartilage inferiorly. The membrane consists of a central stronger and thicker triangular portion and two lateral portions, located directly over laryngeal mucosa. The true vocal cords are usually 10 mm or more above the cricothyroid space.

The superior cricothyroid artery may cross horizontally in the upper third of the membrane. Veins may be found in the pre-tracheal and superficial cervical fascia. One autopsy study of 107 cadavers showed that branch veins  $>2$  mm diameter from the inferior thyroid and anterior jugular veins were found in the midline in 10% of cases, and  $<1$  cm from the midline in a further 31% of cases.<sup>2</sup> Therefore, venous haemorrhage is possible, even with a midline cricothyroidotomy approach. The cricothyroid membrane does not calcify with age and should be readily located in most patients by palpating a dip in the skin below the laryngeal prominence. If normal anatomy is distorted, the little finger can be placed in the suprasternal notch and the index finger should then lie on or near the cricothyroid membrane when all fingers are adjacent to each other and the head is in a neutral position.<sup>1</sup>

## Cricothyroidotomy devices

The ideal device should have the features as listed in Table 2. With a 4 mm device, passive exhalation of 500 ml takes about 4 s; therefore, ventilatory frequency is limited to 10–12 bpm.<sup>3</sup> The minute volume during ventilation with a conventional anaesthetic breathing system is adequate. In contrast, exhalation via a

### Key points

Emergency cricothyroidotomy is rarely undertaken; training on manikins is essential.

After training, skill retention may last only 3–6 months. Regular retraining is therefore required.

Cuffed (as opposed to uncuffed) devices are recommended in the 'can't intubate can't ventilate' scenario.

It is possible to convert from a small cannula technique (allowing oxygenation) to a large-bore cricothyroidotomy device (allowing ventilation).

The Portex Minitrach II is not suitable for use as a rescue ventilation device and has no place on the difficult airway trolley.

**Bhavesh Patel MB BS FRCA**

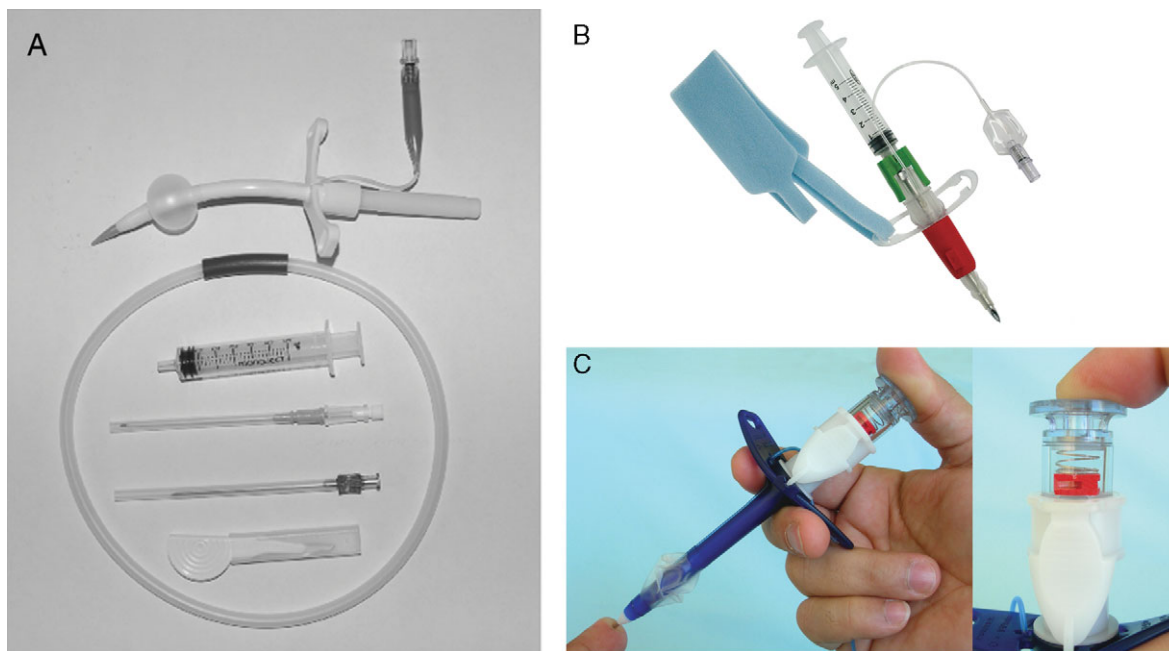
Consultant Anaesthetist  
Royal Surrey County Hospital  
Egerton Road  
Guildford  
Surrey GU2 7XX  
UK

**Christopher Frerk MB ChB FRCA**

Consultant Anaesthetist  
Northampton General Hospital  
Billing Road  
Northampton NN1 5BD  
UK  
Tel: +44 1604 545671  
Fax: +44 1604 545670  
E-mail: chris.frerk@ngh.nhs.uk  
(for correspondence)

**Table 1** Large-bore cricothyroidotomy devices. The Portex™ Minitrach II is designed for tracheobronchial suction and is not licensed for emergency rescue ventilation

Cook Melker		VBM Quicktrach		Portex cricothyroidotomy kit	
Internal diameter (mm)	Length (mm)	Internal diameter (mm)	Length (mm)	Internal diameter (mm)	Length (mm)
Uncuffed 4.0	42	Uncuffed 4.0	42	Cuffed 6.0	90
Uncuffed 4.0	80	Cuffed 4.0	63		
Uncuffed 6.0	75				
Cuffed 5.0	90				



**Fig. 1** Cuffed large-bore cricothyroidotomy devices. (A) Melker kit: 5.0 mm ID cuffed PVC airway with pre-inserted curved dilator, Seldinger wire, 18 G cannula-over-needle, 18 G introducer needle, syringe and scalpel; (B) VBM Quicktrach II 4 mm ID cuffed cannula-over-needle device; (C) Portex PCK 6 mm ID cuffed cannula-over-needle device with red flag indicator (see text). Reproduced with kind permission of David Wong MD.<sup>5</sup>

**Table 2** Ideal characteristics of an emergency cricothyroidotomy device

4.0 mm or larger internal diameter
Cuffed
Able to connect to 15 mm standard anaesthetic circuit and allow ventilation
Design features to minimize collateral damage
Intuitive and easy to learn
Long shelf life
Kink resistant

2 mm ID 14 G cannula takes more than 30 s.<sup>4</sup> It is important that a cuffed device is used (see later). The device should incorporate design features that will minimize complications such as posterior tracheal wall damage and, as the incidence of emergency cricothyroidotomy for a CICV scenario is extremely low (estimates range from 1 in 10 000 to 1 in 50 000), all devices should be easy to use. Even with adequate training, skill retention is an issue. The chosen kit should have a long shelf life.

### Cook Melker device

The Cook Melker is a wire-guided cricothyroidotomy airway (Fig. 1A). Manufactured in a variety of cuffed and uncuffed sizes (Table 1), it is inserted using the Seldinger technique, analogous to insertion of a central venous catheter. The cuffed version comes as a 5.0 mm ID cuffed PVC airway with pre-inserted curved dilator, flexible tip guidewire, 18 G cannula-over-needle, 18 G introducer needle, syringe, and scalpel. It is possible to establish ventilation through a cuffed Melker device in manikins in around 40 s.<sup>5</sup>

The Seldinger wire of this kit can also be passed through a previously placed cannula such as the Ravussin 13 G to convert it to a larger cuffed airway. There is a risk, however, of any cannula kinking (making guidewire insertion difficult) compared with using the rigid 18 G introducer needle, especially if the cannula is not in a 45° caudad direction.

### VBM Quicktrach devices

There are two versions available (Table 1). They are rigid pre-assembled cannula-over-needle devices (Fig 1B) and are inserted as a single-step procedure, avoiding the Seldinger technique. The needle tip is specially designed so that it cuts 2 mm and dilates to 4 mm making prior skin incision unnecessary. A stopper distal to the needle hub reduces the risk of posterior tracheal wall injury by limiting depth of insertion of the needle.

The uncuffed Quicktrach I is short, prone to displacement, and may not be long enough to enter the trachea if the neck is large. The Quicktrach II is a cuffed, longer 4.0 mm ID device that has a safety clip which avoids the metal needle being pushed out of the cannula once it has been retracted (Table 1). The cannula is malleable enough to adapt to the contours of the trachea. It is possible to achieve ventilation in a manikin in approximately 20 s with Quicktrach I and 30 s with Quicktrach II.

### Portex cricothyroidotomy kit

This is also a rigid cannula-over-needle device packaged as a pre-assembled set with scalpel and 10 ml syringe (Fig. 1C). A spring-loaded Veress needle with blunt stylet is nestled in an integral dilator over which a 6 mm ID cuffed airway fits. There is a small red flag indicator in the needle hub which disappears with loss of tissue contact indicating intratracheal placement. One manikin study has shown insertion time to be around 30 s.<sup>5</sup>

### Portex Minitrach II

The Minitrach II is a wire-guided kit that provides an uncuffed 4.0 mm ID airway. It is designed for tracheobronchial suction, *not* emergency ventilation. It is not easy to insert quickly; assembly of its components requires several discrete steps in the correct sequence. The needle tip is blunt and may not actually perforate the CTM but lead to pre/para-tracheal insertion. The guidewire is not J-tipped. The Minitrach II took significantly longer (150 s) to establish first ventilation in pig larynxes with a higher rate of injury to the posterior tracheal wall compared with the Quicktrach I (48 s).<sup>6</sup>

### Factors affecting device performance

The key decision when planning which device to stock on difficult airway trolleys is whether to choose a wire-guided kit with several pieces of equipment or to use the simpler cannula-over-needle device which involve a simple ‘push and go’ technique.

Device diameter and curvature are important. The Melker has a curved shape whereas the Portex PCK is rigid, rectilinear and has a higher incidence of posterior tracheal wall damage in cadavers. Small pilot needles guide insertion of large cannulae and minimize complications such as posterior tracheal wall penetration and para-tracheal deflection. There will be a ‘giving way’ of the CTM at the moment of maximal insertion force and this affects controllability

of device insertion. This may explain the 18% incidence of damage to the larynx seen in one cadaver study with the ‘push and go’ technique of the Quicktrach I.<sup>7</sup>

### Skin incision

Both Cook and Portex recommend an adequate skin incision before inserting the needle and provide a blade in their pre-assembled kits. If the 18 G cannula-over-needle is used in the Melker set, the cannula is less likely to kink if there is a skin incision.<sup>1</sup> This will allow the guidewire, dilator, and airway to pass easily. Although the VBM Quicktrach guidelines do not recommend a skin incision, it has been shown in a cadaver study that prior skin incision allowed the Quicktrach I to be inserted faster (35 vs 83 s).<sup>7</sup>

As stated earlier, arteries lie deep to the pretracheal fascia and should be avoided if skin incision is kept superficial. There is no clear consensus as to whether a horizontal or vertical incision is more likely to avoid vessel injury. A vertical skin incision over the lower third of the space allows accurate palpation of the cricothyroid membrane. This incision can then be extended if there has been movement of the skin. A horizontal stab incision should be made through the lower third of the cricothyroid membrane, bearing in mind that the cricothyroid arteries often anastomose in the midline superiorly.

### Cuffed vs uncuffed airways

In addition to leaving the airway unprotected and increasing the risk of gastric distension, uncuffed 4 mm ID airways provide sub-optimal ventilation. During the CICV scenario, complete upper airway obstruction is rare and gas can escape proximally leading to decreased minute volume or complete failure to ventilate the lungs. This is especially likely if lung compliance is low. Model studies with uncuffed devices have shown that minute volume increases only when upper airway obstruction is increased.<sup>8</sup> In real-life scenarios, this situation has been managed by deliberately obstructing the upper airway with saline-soaked throat packs or inserting an LMA with the 15 mm connector occluded. One model study showed similar minute volumes between a surgical 6.0 mm ID tracheostomy tube and the cuffed Melker 5.0 mm ID device, whereas the uncuffed Melker 6.0 mm ID device failed to achieve adequate ventilation.<sup>9</sup> The cuffed Melker took no longer to insert than the uncuffed device. It is for this reason that uncuffed 4 mm tubes cannot be recommended for management of the CICV scenario.

### Large-bore cricothyroidotomy devices vs surgical cricothyroidotomy

Most anaesthetists are unfamiliar with surgical cricothyroidotomy techniques and are reluctant to resort to them in an emergency when needed. The rapid four-step surgical cricothyroidotomy technique, described in the Difficult Airway Society 2004 guidelines,

**Table 3** Complications of cricothyroidotomy<sup>1</sup>

Early	Late
Bleeding	Tracheal and subglottic stenosis
Unsuccessful placement	Aspiration
Posterior tracheal wall perforation	Swallowing dysfunction
Pneumothorax/emphysema	Tracheo-oesophageal fistula
Airway obstruction	Voice change
Vocal cord injury	Infection
Aspiration	Late bleeding
Laryngeal cartilage fracture	Stoma
Oesophageal/mediastinal perforation	Tracheomalacia

has been shown to take a mean of 43 s to establish an airway in human cadavers.<sup>10</sup> The Advanced Trauma Life Support adds blunt dissection with the scalpel handle once the horizontal stab incision has been made. However, there is a risk, when neck anatomy is difficult, that the incision made in the cricothyroid membrane may be difficult to locate subsequently.

There is no consensus as to whether a surgical cricothyroidotomy leads to faster effective ventilation compared with large-bore cricothyroidotomy techniques. Studies vary and are limited to manikins, human cadavers, or animals and therefore do not simulate real-life bleeding, time pressure, tissue oedema, and elasticity. The Melker device produces a smaller neck wound compared with surgical cricothyroidotomy and this decreases the chances of bleeding.<sup>11</sup> Misplacement and cartilage fracture rates were similar in this human cadaver study.

The wire-guided Melker system is preferred by some anaesthetists to surgical cricothyroidotomy because of the familiarity of the Seldinger technique and the perceived decreased risk of bleeding.<sup>9,11</sup> Those who prefer the surgical technique cite speed and simplicity as important factors.

## Training

Elective cricothyroidotomy with small cannula techniques for head and neck surgery and trans-tracheal local anaesthetic topicalization before awake intubation allow development of the requisite skills for inserting cannulae through the cricothyroid membrane. Percutaneous tracheostomies in the ICU offer valuable experience in cannulating the trachea. It is also useful to palpate the cricothyroid membrane in as many patients as possible, especially those with a 'difficult' neck.

Taking advantage of these opportunities, while of some benefit, is no substitute for dedicated training in cricothyroidotomy. It has been shown that training on pig larynx preparations reduces time to successful ventilation and reduces complications. Training on manikins also decreases time to successful ventilation. Using medium or high-fidelity simulators with audible decreasing pitch desaturation leads to a more realistic and stressful scenario compared with a manikin and improves both practical and decision-making skills. Even with these simulators, it is

very difficult to simulate bleeding and a 'difficult' neck for training purposes.

It has been shown that, regardless of prior experience, it takes five successive cricothyroidotomies using the Melker kit in manikins to reach a plateau in the learning curve.<sup>12</sup> After training and five attempts, 96% of anaesthetists are able to achieve successful ventilation in <40 s. Regular re-training is essential as the benefits of training last only 4–8 months.

## Conclusion

Although the likelihood of having to use a cricothyroidotomy device in the course of an individual's career is low, the need for rapid success is high. There are significant complications (Table 3). Regular training significantly reduces insertion times and misplacement rates.

## References

- Melker RJ, Florete OG. Percutaneous dilational cricothyrotomy and tracheostomy. In: Benumof JL, ed. *Airway Management: Principles and Practice*. St Louis, MO: Mosby, 1996; 484–512
- Goumas P, Kokkinis K, Petrocheilos J, Naxakis S, Mochloulis G. Cricothyroidotomy and the anatomy of the cricothyroid space. An autopsy study. *J Laryngol Otol* 1997; **111**: 354–6
- Dworkin R, Benumof JL, Benumof R, Karagianes TG. The effective tracheal diameter that causes air trapping during jet ventilation. *J Cardiothorac Anesth* 1990; **4**: 731–6
- Ryder IG, Paoloni CC, Harle CC. Emergency transtracheal ventilation: assessment of breathing systems chosen by anaesthetists. *Anaesthesia* 1996; **51**: 764–8
- Assmann NM, Wong DT, Morales E. A comparison of a new indicator-guided with a conventional wire-guided percutaneous cricothyroidotomy device in mannequins. *Anesth Analg* 2007; **105**: 148–54
- Fikkers BG, van Vugt S, van der Hoeven JG, van den Hoogen FJ, Marres HA. Emergency cricothyrotomy: a randomised crossover trial comparing the wire-guided and catheter-over-needle techniques. *Anaesthesia* 2004; **59**: 1008–11
- Frei FJ, Meier PY, Lang FJ, Fasel JH. Cricothyrotomy using the Quicktrach coniotomy instrument set. *Anaesth Intensivther Notfallmed* 1990; **25**: 44–9
- Craven RM, Vanner RG. Ventilation of a model lung using various cricothyrotomy devices. *Anaesthesia* 2004; **59**: 595–9
- Sulaiman L, Tighe SQ, Nelson RA. Surgical vs wire-guided cricothyroidotomy: a randomised crossover study of cuffed and uncuffed tracheal tube insertion. *Anaesthesia* 2006; **61**: 565–70
- Henderson JJ, Popat MT, Latto IP, Pearce AC. Difficult Airway Society guidelines for management of the unanticipated difficult intubation. *Anaesthesia* 2004; **59**: 675–94
- Chan TC, Vilke GM, Bramwell KJ, Davis DP, Hamilton RS, Rosen P. Comparison of wire-guided cricothyrotomy versus standard surgical cricothyrotomy technique. *J Emerg Med* 1999; **17**: 957–62
- Wong DT, Prabhu AJ, Coloma M, Imasogie N, Chung FF. What is the minimum training required for successful cricothyroidotomy? A study in mannequins. *Anesthesiology* 2003; **98**: 349–53

Please see multiple choice questions 6–9