

Anaesthesia for magnetic resonance imaging

Ugan Reddy BSc FRCA
Mark J White MPhys PhD
Sally R Wilson BSc FRCA



Key points

Magnetic resonance imaging (MRI) is based on the interactions between a static magnetic field generated by the scanner and the tiny fields that arise from individual atomic nuclei.

MRI produces particularly good images of soft tissue and provides greater contrast between different types of tissue than other imaging modalities.

There are numerous safety concerns associated with the MRI environment.

Many patients require general anaesthesia or sedation for MRI because of the need to minimize movement during potentially long scanning times and the noisy and claustrophobic environment of the scanner.

All equipment must be compatible with the MR environment and allow safe anaesthesia and adequate monitoring in this setting.

Ugan Reddy BSc FRCA

Department of Neuroanaesthesia
The National Hospital for Neurology and Neurosurgery
University College London Hospitals
NHS Foundation Trust, Queen Square
London WC1N 3BG, UK

Mark J White MPhys PhD

Lysholm Department of Neuroradiology
The National Hospital for Neurology and Neurosurgery
University College London Hospitals
NHS Foundation Trust, London, UK

Sally R Wilson BSc FRCA

Department of Neuroanaesthesia
The National Hospital for Neurology and Neurosurgery
University College London Hospitals
NHS Foundation Trust, Queen Square
London WC1N 3BG, UK
Tel: +44 (0)20 7829 8711
Fax: +44 (0)20 3448 4734
E-mail: sally.wilson@uclh.nhs.uk
(for correspondence)

Magnetic resonance imaging (MRI) is a frequently used technique that produces particularly good images of soft tissue, providing greater contrast between different types of tissue than computerized tomography scans. It is used extensively for imaging the central nervous, musculoskeletal, and cardiovascular systems, and also the pelvis and liver. More recently, MRI technology has evolved to fulfil the needs of demanding new clinical domains, including an active role inside the operating theatre. All equipment must be compatible with the MR environment and allow safe anaesthesia and adequate monitoring in this setting. The incorporation of MRI technology into the operating theatre brings additional challenges.

Principles of MRI

Physics of MRI

MRI is based on the interactions between a static magnetic field generated by the scanner and the tiny fields that arise from individual atomic nuclei. Some species of nuclei have a net spin which gives them a magnetic dipole moment and, when placed within another magnetic field, they orient themselves at a slight angle to the external field—either almost parallel or almost opposed to it. The nuclei also precess around the direction of the magnetic field at a frequency proportional to the field strength. (Precession is a wobbling motion that occurs when a spinning object is subject to an external force.) MRI exploits the slight energy difference between these two states and, by applying an oscillating magnetic field at the frequency of precession, additional nuclei can be moved from the lower (parallel) to the higher (antiparallel) energy state. As the nuclei relax back to their original states, they re-emit energy at the same frequency and this is

detected by a receiving coil in the scanner. Most clinical systems are tuned to interact with the hydrogen nuclei in water and, as they precess at just under 64 MHz at the commonly used scanner field strength of 1.5 T, the transmitted and received fields are in the radiofrequency (RF) range. Images are generated by perturbing the uniform 1.5 T static field with small, dynamic gradient fields, allowing spatial localization of the received signal by introducing slight spatial variations in the precession frequency.

Contrast

Contrast between tissues is generated in a number of ways during MRI. In addition to variations in the density of hydrogen nuclei between tissues, the physical and chemical properties of different tissues cause their nuclei to relax to their resting states at different rates, thus creating different levels of detected RF. There are two distinct mechanisms of relaxation with separate time constants—T1 and T2. In T1-weighted images, fat appears bright (high signal) and water dark, whereas T2-weighting results in fat appearing darker than water. Thus, cerebrospinal fluid is bright on a T2-weighted image and dark on a T1-weighted image. T1-weighting provides good grey–white matter contrast on brain images and T2-weighting identifies tissue oedema clearly.

I.V. contrast agents may also be administered and the most common are chelates of gadolinium, which alter the relaxation rates of hydrogen nuclei. These can occasionally cause mild side-effects, including nausea, vomiting, and pain on injection, and there is a recognized, albeit low, incidence of anaphylactoid reactions. However, gadolinium-based contrast agents have been implicated in causing nephrogenic systemic fibrosis (NSF) in patients with

doi:10.1093/bjaceaccp/mks002

Advance Access publication 26 February, 2012

Continuing Education in Anaesthesia, Critical Care & Pain | Volume 12 Number 3 2012

© The Author [2012]. Published by Oxford University Press on behalf of the British Journal of Anaesthesia.

All rights reserved. For Permissions, please email: journals.permissions@oup.com

impaired renal function and it is usual to assess renal function by measuring an estimated glomerular filtration rate in all patients receiving gadolinium.^{1,2} Although all commercially available linear chelates of gadolinium have been reported to cause NSF, the majority of cases are related to gadodiamide.¹ There is also an increased incidence of NSF in patients with concurrent liver disease.

Other, more complex, contrast mechanisms are also possible during MRI. For example, the gradient fields can be manipulated, such that increased local water diffusion further attenuates the received RF signal.

MRI scanner design

Medical MRI scanners typically use field strengths between 0.5 and 3 T, with most general diagnostic scanners currently operating at 1.5 T—around 30 000 times the Earth's geomagnetic field. They have a cylindrical-bore design with the static field maintained by a superconducting solenoid within a dewar of liquid helium.

The body part being scanned is usually placed at the centre of the field and, with the traditional, cylindrical MR scanner design, the patient is thus within the bore of the magnet. This limits access to the patient by the anaesthetists and may not be tolerated by claustrophobic patients.³

A fringe field extends around the scanner, with its shape determined by the magnet's design. Field strengths at the scanner bore are quantified in Tesla, but the smaller values associated with safety limits around the fringe field are usually described in gauss (G), where 1 T=10 000 G. The Earth's geomagnetic field is around 0.5 G.

Alternative MRI scanner designs can broadly be classified as 'open' systems, using a pair of magnets, which may be superconducting, permanent, or conventional electromagnets. Open magnets have traditionally been popular for interventional applications and remain important where procedures such as lesion biopsy or cardiac catheterization are performed under direct image guidance. This arrangement has the advantage of immediate or even continuous imaging, but places limitations on intervention. The procedure takes place within a confined space and may only utilize non-ferrous instruments within the magnet, with their added cost and decreased durability compared with steel equivalents (see below). Open magnet designs also typically use lower field strengths which reduces imaging quality unless scanning times are increased.

Safety of MRI

MR hazards can be divided into five broad categories.

The static magnetic field

Ferromagnetic objects within the 30 G contour will experience both an attractive force (i.e. they will be pulled towards the centre of the magnet) and a torque (i.e. they will attempt to line up with

the field). With most modern MRI scanners, the magnetic field is always on, even between scans, so constant vigilance is important. Even quite small objects become dangerous projectiles sufficient to injure or kill anyone in their path, and larger objects can trap or crush a patient or staff member. Foreign bodies in the eye may become dislodged, leading to vitreous haemorrhage. Implanted pacemakers, defibrillators, and other devices may be inactivated, re-programmed, dislodged, or converted to an asynchronous mode by the magnetic field. To avoid such incidents, nobody (patient or staff) should pass the 5 G contour without first undergoing an MR safety check for implantable devices and other contraindications.⁴ Although implanted programmable devices are typically a contraindication to having an MRI scan, some patients may be scanned under strictly controlled conditions in specialist centres.

Time-varying magnetic gradient fields

Smaller dynamic magnetic fields are manipulated rapidly during image acquisition and can induce a current sufficient to stimulate the peripheral nerve and muscle cells, sometimes causing discomfort. Medical MRI scanners apply limits on gradient field manipulation to avoid the more extreme consequences of induced currents such as limb movement or ventricular fibrillation.

Acoustic noise

The switching of the gradient fields creates loud acoustic noise, typically above the safe level of 85 dB. This can potentially cause hearing loss, especially during long scans, and staff and patients (awake or anaesthetized) must wear ear protection.⁴

RF heating

A powerful radio transmitter interacts with patient tissue at the resonant frequency of the scanner and can lead to power dissipation (potentially non-uniform) within the patient and a corresponding increase in temperature. The scanner continuously monitors RF power to limit this effect, although other factors such as ambient temperature, airflow, humidity, and clothing also play a role. RF heating also creates a risk of severe and rapid burns from any conductive material left on the patient's skin, so contact with the metal in clothing, RF coils, ECG leads, and other equipment must be avoided.

Helium escape

When a superconductor is used to maintain the main static magnetic field, the cryostat typically contains around 1000 litres of liquid helium within a few degree Celsius of absolute zero. In the event of a spontaneous or emergency field shutdown, known as a quench, the liquid helium expands to gas and must be vented very rapidly. The MRI suite is designed to vent this outside the building via a quench pipe but, if this fails or becomes blocked, some or all of the gas may enter the suite necessitating rapid evacuation. MRI

suites usually have oxygen sensors, ventilation controls, and a pressure equalization mechanism to alert staff and ensure that the door can always be opened in the event of a quench.

Monitoring and equipment

Equipment used in the MR unit may be designated *MR safe*, *conditional*, or *unsafe*.⁵ *MR safe* devices pose no known additional MR-related hazards in any MR environment, whereas *MR conditional* equipment poses no hazard in a specified MR environment during specific conditions of use. Various conditions may be applied to this definition, including limits on static field strength, spatial gradient, rate of change of magnetic field, RF fields, and specific absorption rate, or configuration of the equipment itself. Equipment known to pose a hazard in all MR environments is designated *MR unsafe*.

Monitoring in the MR unit must conform to the same standards as in the operating theatre. Since individual MR scanners vary with regard to the magnetic fringe field, and also their operating range for other critical parameters, the use and placement of MR conditional equipment must be considered separately for each scanner in association with advice from the local physicist.⁵ All monitoring equipment used in the MRI scanner should be designed for use in this environment and is typically designated *MR conditional*. Most modern monitoring equipment is telemetric, thereby avoiding the need for long electrical connections between the patient and monitor, and is either battery-powered or has an isolated power source. Batteries themselves may be strongly ferromagnetic, although some battery-powered equipment is *MR conditional*. The Association of Anaesthetists recommends that all monitoring equipment should be placed in the control room outside the magnet room.⁵

There have been several case reports of severe burns resulting from induction currents when standard pulse oximeters have been used in the MRI environment. Fiberoptic probe connections in MRI-safe pulse oximeters are therefore preferable. The ECG is also prone to interference from current induction in the leads, resulting in spikes on the ECG trace, and T-wave amplitude and ST-segment changes. This makes arrhythmias and ECG morphological changes difficult to detect. The effects of induction currents on the ECG are reduced by using high impedance, braided, short leads, and MRI-safe electrodes placed in a narrow triangle on the patient's chest. Locating the electrodes close together ensures a high amplitude signal. *MR safe* electrodes use fiberoptic cables, transmit the ECG signal by means of light rather than electric current, and are more resilient to electromagnetic effects. Purpose-designed MRI equipment may also have the ability to partially filter the ECG signal for currents induced by time-varying magnetic fields. Non-invasive arterial pressure monitoring is relatively easily accomplished if ferrous connections are changed to nylon. For invasive pressure monitoring, the length of pressure lines should be minimized to reduce damping. Capnography is complicated by the use of long sampling lines and

an increase in the time delay (up to 20 s) of the displayed waveform.

Sedation and anaesthesia for MRI

An MRI study usually consists of multiple image sequences, each taking up to 10 min to acquire, and any movement during this time will produce profound distortion of the final images. The number and duration of scans is variable, with some complex studies lasting up to 2 h. The MRI is a noisy and claustrophobic environment with restricted access to the patient. The aims of anaesthesia are therefore to provide immobility to obtain the best possible images, while maintaining patient safety and comfort throughout. This is achieved by either sedation or general anaesthesia, both of which require meticulous organization, education, and training of all staff involved.

Sedation

In paediatric practice, sedation for MRI is widely delivered by multi-disciplinary teams (including non-physician-led teams) with great success. The goals of sedation for diagnostic and therapeutic procedures are to guard the patient's safety and welfare, minimize physical discomfort and pain, control anxiety, maximize the potential for amnesia, and control behaviour and movement.⁶

All patients require a careful pre-sedation evaluation, appropriate fasting for elective procedures and a focused airway examination. Safe delivery of sedation requires appropriate levels of physiological monitoring, equipment for emergency airway management, and venous access. Owing to the noisy, claustrophobic environment of the MRI scanner, and the need to minimize movement for enhanced image quality, deep sedation is needed for the duration of the scan. If hypoventilation or other problems arise, stopping the scan, pulling the scanning table outside the magnet bore, and attending to the patient in this isolated setting is time-consuming and requires expert knowledge and regular practice.⁷

A variety of drugs are useful for sedation and a clear understanding of the pharmacokinetic and pharmacodynamic effects of the individual agent is vital when choosing the most appropriate drug for a particular patient/scenario. Propofol is often an excellent choice as it provides effective sedation, easy titration to the required sedation level, and short recovery times. In a paediatric study, propofol was associated with shorter ready to scan and discharge times compared with choral hydrate and pentobarbital. Propofol sedation is also safe; in a study in 249 paediatric patients (mean age 4.8 yr), propofol sedation was rarely associated with unanticipated adverse effects (<1%).

General anaesthesia

In many cases, particularly for longer scans or particular patient groups, general anaesthesia is required (Table 1). It is helpful for the anaesthetist to understand the quality and detail of the images

Table 1 Patients requiring anaesthesia for MRI

Infants and children with neurological disease, vascular malformations, or oncological tumour growth
Children or adults with learning disorders
Patients with severe movement disorders
Patients whose position is limited by pain
Claustrophobic patients
Ventilated and other ITU patients
Certain patients undergoing stereotactic neurosurgical procedures
Patients having surgery with intraoperative MRI

required, and also the likely duration of the scan, since this information will determine whether spontaneous ventilation via a laryngeal mask airway (LMA), or tracheal intubation and ventilation, is indicated.

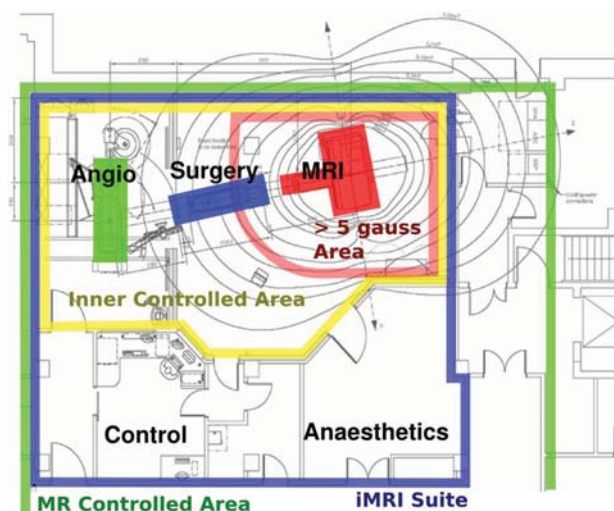
Anaesthesia should be induced in a dedicated anaesthetic room adjacent to the MRI scanner but outside the 5 G contour. This provides an area in which standard anaesthetic and resuscitation equipment can be stored and used. The location of the anaesthetic room should be such that anaesthetized patients can be easily and rapidly transferred into the scanner and rapidly retrieved in an emergency. Patients should be transferred into the scanning room on an MRI-safe non-ferrous trolley.

The airway of the patient who goes head first into the magnet (as is usual for the head or upper body imaging) is completely inaccessible. In addition, the receiver coil is placed around the area being examined and this further restricts access to the airway during head scans. The anaesthetist must therefore be satisfied with the security of the airway before the commencement of the scan. The LMA is widely used during MRI examinations and a mask with no ferromagnetic components must be chosen. The pilot balloon of cuffed tracheal tubes contains a small ferromagnetic spring and this should be taped away from the area to be scanned.

During scanning, maintenance of anaesthesia can be achieved through i.v. or inhalation techniques. Standard infusion pumps are strongly ferromagnetic, become projectiles in the MRI environment, and malfunction if placed near the magnetic field. MRI conditional infusion pumps with relatively high static field limits are widely available and allow for total i.v. anaesthesia to be used safely in this environment. Recently, MRI-safe infusion pumps have been developed. MR compatible anaesthetic machines and ventilators can be sited adjacent to the magnet bore, minimizing the length of the breathing system and allowing for the safe delivery of volatile anaesthesia. If these are unavailable, a standard machine can be secured firmly to a wall outside the 5 G contour, with the exact location determined by the local physicist.

Intraoperative MRI

Intraoperative MRI (iMRI) offers the advantage of near real-time imaging guidance during neurosurgical procedures. Other image-guided neurosurgical techniques are based on scans acquired

**Fig 1** The layout of an iMRI suite.

before operation and, as there may be a significant brain shift during resection, navigational accuracy decreases as the surgery proceeds. iMRI allows the surgeon to scan the patient at appropriate intervals during surgery and provides improved, real-time navigation accuracy with accurate lesion resection and the confidence to end the procedure in the knowledge that excision is complete.⁸ Intraoperative imaging can also remove the need for a postoperative scan. iMRI contributes to enhanced clinical outcomes, improved patient care, and possible economic savings if repeated surgeries can be avoided.

The successful use of iMRI during neurosurgery has been reported in tumour surgery [ventricular tumours, gliomas (particularly low grade), and difficult pituitary tumours], epilepsy surgery including the placement of depth electrodes, and deep brain stimulation surgery.⁹ Other uses of iMRI include the biopsy of the liver and breast lesions that allows for accurate and early diagnosis. MR-guided thermal ablation is also increasingly being used as a minimally invasive alternative to open surgery for a variety of oncological applications. Endoluminal MR interventions, such as MR-angioplasty, and interventions for other tubular structures, for example, biliary ducts, are also gaining popularity.

A typical iMRI suite (Fig. 1) comprises an inner controlled area in which projectile hazards exist (i.e. >30 G) and a larger MR-controlled area where hazards exist in relation to implanted devices (i.e. >5 G), and to which physical access is controlled with self-locking doors/entry cards. The presence of a large multi-disciplinary team in the iMRI suite highlights the need for compulsory safety induction and training courses, and defined patterns of workflow. During surgery, an MRI responsible person, usually a senior radiographer, controls the flow of staff and equipment through the environment.

If the operating table is located within the 5 G area, all surgical instruments should be MR safe, that is, non-ferrous, and this has enormous cost implications. An alternative arrangement is to

locate the operating table outside the 5 G line, facilitating the use of the full range of surgical instrumentation, with efficient transfer into the magnet to obtain diagnostic-quality images at any point during the procedure.

Merging the MRI suite into the operating theatre creates a great challenge for all staff, but particularly the anaesthetist. The concerns over safety, physiological monitors and equipment are the same as in the conventional MRI environment but associated also with potentially complex neuroanaesthetic management. Prolonged operating times, repeated intraoperative scans, difficult intraoperative thermoregulation, and meticulous attention to patient positioning on the operating table and during the transfer into the scanner bring additional challenges.⁸ Both total i.v. anaesthesia and volatile anaesthetic agents have been successfully used in this environment.

Declaration of interest

None declared.

References

1. Bongartz G. Imaging in the time of NFD/NSF: do we have to change our routines concerning renal insufficiency? *MAGMA* 2007; **20**: 57–62
2. Kei PL, Chan LP. Gadolinium chelate-associated nephrogenic systemic fibrosis. *Singapore Med J* 2008; **49**: 181–5
3. Peden JC, Twigg SJ. Anaesthesia for magnetic resonance imaging. *Contin Educ Anaesth Crit Care Pain* 2003; **4**: 97–101
4. MHRA. *Devices Bulletin: Safety Guidelines for Magnetic Resonance Imaging Equipment in Clinical Use*. London, December 2007
5. Association of Anaesthetists of Great Britain and Ireland. Safety in magnetic resonance units: an update. *Anaesthesia* 2010; **65**: 766–70
6. Schulte-Uentrop L, Goepfert MS. Anaesthesia or sedation for MRI in children. *Curr Opin Anesthesiol* 2010; **23**: 513–7
7. Serafini G, Zadra N. Anaesthesia for MRI in the paediatric patient. *Curr Opin Anesthesiol* 2008; **21**: 499–503
8. Bergese SD, Puente EG. Anaesthesia in the intraoperative MRI environment. *Neurosurg Clin N Am* 2009; **20**: 155–62
9. Barua E, Johnston J, Fuji J *et al*. Anaesthesia for brain tumour resection using intraoperative magnetic resonance imaging (iMRI) with the Polestar N-20 system: experience and challenges. *J Clin Anaesth* 2009; **21**: 371–6

Please see multiple choice questions 25–28.