

# Anaesthesia for awake craniotomy

Cally Burnand BMedSci BMBS FRCA

Joseph Sebastian BSc MBBS MRCP FRCA



## Key points

Awake craniotomy is an important technique for increased lesion removal and minimizing damage to eloquent cortex.

An important aspect of an awake craniotomy is the preoperative patient selection and preparation by the multi-disciplinary team.

There is no recognized consensus on the best anaesthetic approach to an awake craniotomy. This is because the anaesthetist varies the technique dependent on the surgeon, pathology, length of surgery, and patient factors.

Cortical mapping and clinical monitoring aim to localize eloquent brain areas.

The role of the awake craniotomy has increased recently; however, technology that allows functional brain mapping are being developed.

The awake craniotomy is an important technique used for brain tumour excision from eloquent cortex, epilepsy surgery, and deep brain stimulation surgery. It has been used, less commonly, in the management of mycotic aneurysms and arteriovenous malformations near critical brain areas.

The benefits are considered to be of increased lesion removal, with growing evidence of improved survival benefit,<sup>1</sup> whilst minimizing damage to eloquent cortex and resulting post-operative neurological dysfunction. Other advantages include a shorter hospitalization time, hence reduced cost of care, and a decreased incidence of postoperative complications such as nausea and vomiting.

The concept of an awake craniotomy pre-dates the existence of anaesthesia and in ancient times, trephining of the skull was used to get rid of 'evil air'.<sup>2</sup> It is a procedure that has gained in popularity because of advances in diagnosis, intra-operative functional neurosurgical technology, developments in anaesthetic agents and monitoring, and the patient's expectations.

The term 'awake craniotomy' is misleading as the patient is not fully awake for the entirety of the procedure. The more surgically stimulating parts of the procedure require varying levels of sedation, or anaesthesia. The patient is fully awake during the mapping procedure during which lesion resection takes place.

The common anaesthetic techniques used are sedation only or general anaesthesia, and awaking the patient for cortical mapping and resection, with the option of re-anaesthetizing for closure. The patient has a scalp block inserted for pain relief usually for all anaesthetic approaches. Occasionally the anaesthetic technique of awake with a scalp block alone is utilized, this can be useful in elderly patients.

The anaesthetic considerations for an awake craniotomy can make it challenging, and this article will consider the issues involved.

and psychological prerequisites to avoid failure intra-operatively. All patients should have consultations with the neurosurgeon and the anaesthetist.

These consultations allow the assessment of patient suitability (see Table 1 for absolute and relative contraindications), and preparation of the patient for the procedure. This involves a full assessment of the patient's co-morbidities, which should be optimized before operation, in order to decrease intra-operative failure of the awake technique. It is also important to be aware of how the patient's presenting problem for surgery affects them, for example, seizure type and frequency or the presence of preoperative neurological deficits.

Preoperative preparation includes providing detailed information to the patient. The patient must know what to expect and the anaesthetic risks involved. This usually includes verbal and written information. Occasionally the patient is helped by visiting the theatre and visualizing the environment and equipment involved.

Patients may be seen by the neuropsychologist before operation if the lesion involves speech and language centres, and their baseline responses to picture cards are assessed and recorded.<sup>3</sup> In some neurosurgical centres, the neuroanaesthetist performs the role of functional assessment in theatre.

These preoperative visits provide an invaluable opportunity for the multidisciplinary team to create a rapport with the patient and therefore encourage trust and familiarity.

## Theatre preparation

It is vital that communication between the anaesthetist and surgeon is effective and this is often aided by ensuring familiarity and discussion of the operative plan in detail. It is imperative that the plan for anaesthesia and surgery is well communicated to all the members of the theatre team.

As in all surgical cases, equipment should be checked and patient scans should be available before commencing. The operating table must be made as comfortable as possible as the patient may be lying in one position for several

### Cally Burnand BMedSci BMBS FRCA

Consultant Anaesthetist  
Salford Royal Foundation Trust  
Stott Lane  
Salford  
M6 8HD  
UK  
E-mail: callyburnand@srf.t.nhs.uk  
(for correspondence)

### Joseph Sebastian BSc MBBS MRCP FRCA

Consultant Anaesthetist  
Salford Royal NHS Foundation Trust  
Stott Lane  
Salford  
M6 8HD  
UK

## Preoperative

One of the most important considerations is careful patient selection. There are both physical

doi:10.1093/bjaceaccp/mkt024

Advance Access publication 19 June, 2013

Continuing Education in Anaesthesia, Critical Care & Pain | Volume 14 Number 1 | 2014

© The Author [2013]. Published by Oxford University Press on behalf of the British Journal of Anaesthesia.

All rights reserved. For Permissions, please email: journals.permissions@oup.com

**Table 1** Anaesthetic contraindications

Absolute
Patient refusal
Inability to lay still for any length of time
Inability to co-operate, for example confusion
Relative
Patient cough
Learning difficulties
Inability to lay flat
Patient anxiety
Language barriers
Obstructive sleep apnoea
Young age

hours. The temperature of the operating theatre should be comfortable for the patient, and staff numbers should be minimized to alleviate unneeded noise and patient anxiety.

Consideration should be given to the operating theatre layout and position of the patient. The ability to communicate with the patient should be maintained at all times and of equal importance is access to the patient during adverse incidents.<sup>4</sup>

The patient position is dictated by the location of the lesion. This is usually a lateral or supine position, but with occipital lesions and testing the visual cortex, a sitting position may be used. In any position, it is important that when the patient is fully awake during mapping that they are able to see and communicate with the

anaesthetist or neuropsychologist. Sterile drapes used must not encroach over the patient's face as this can cause patient claustrophobia and difficulty communicating.

A typical operating theatre layout is shown in Figure 1.

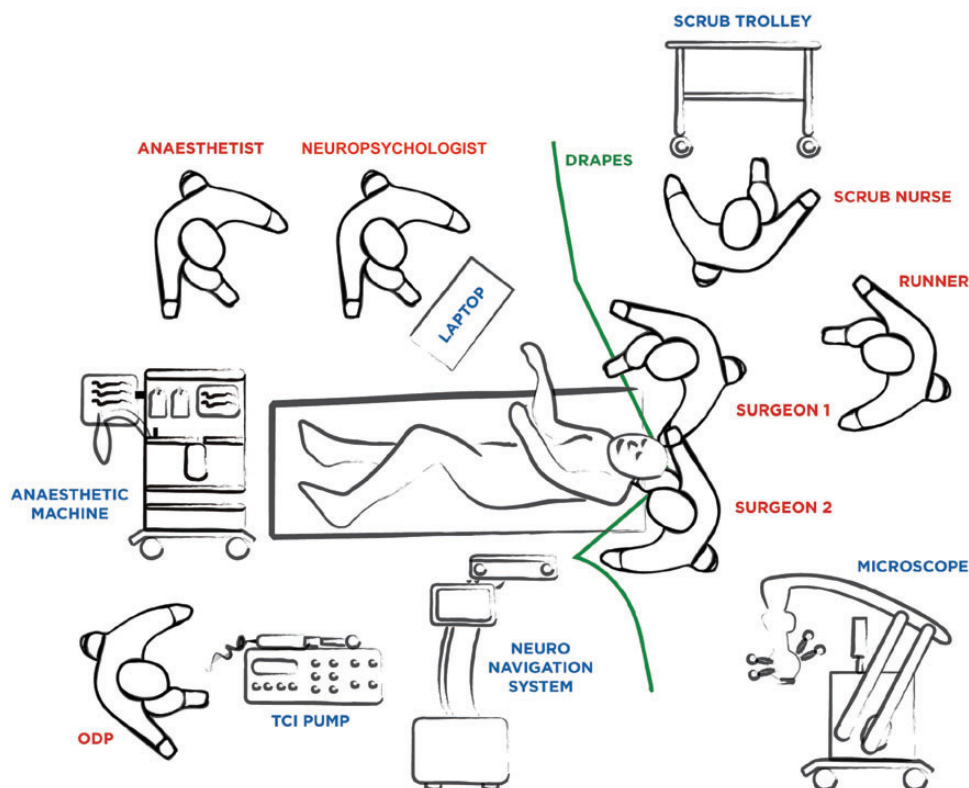
### General anaesthetic principles

Premedication is not common, but consideration must be given to acid reflux prophylaxis, and patients must take their usual steroid, anti-epileptic, or anti-hypertensive medication. Some neurosurgical centres may load the patient with anti-convulsants on the day of surgery or check for therapeutic plasma levels of anti-convulsants if patients are already on them.

Standard anaesthetic monitoring is applied as according to the Association of Anaesthetists of Great Britain and Ireland guidelines. Large-bore intravenous access is gained and the majority of anaesthetists insert an arterial line, usually sedated or asleep.

The use of other forms of monitoring is variable. Depth of anaesthesia monitors, for example bispectral index monitoring (BIS™), is sometimes utilized and there is some suggestion that its use reduces the amount of anaesthetic agents administered, and hence the time taken for patient emergence and co-operation for cortical mapping.<sup>5</sup>

Urinary catheterization can cause discomfort and intolerance of the procedure; some centres use urinary convenes.<sup>6</sup> When urinary



**Fig 1** Theatre layout for an awake craniotomy.

catheterization is not used, the judicious use of fluids must be considered.

Capnography whilst under a general anaesthetic is considered basic monitoring, but carbon dioxide monitoring for patients who are sedated or awake during mapping is also common practice. Although the carbon dioxide levels may be inaccurate, it is used to confirm ventilation.

Anaesthetic drug choice even within a preferred anaesthetic technique varies, but the general principles are common to all; the need to maximize patient comfort, the prevention of nausea and vomiting which can increase intracranial pressure, the need for haemodynamic stability, and the use of short-acting drugs that allow acute control of a patient's conscious level.<sup>3</sup>

All patients will receive prophylactic antibiotics pre-incision, and usually one or more anti-emetics. The most common choices are ondansetron, cyclizine, and dexamethasone.<sup>6</sup> Dexamethasone may also be used to aid the condition of the brain intra-operatively. Intra-operatively paracetamol and rarely non-steroidal anti-inflammatory drugs are used for analgesia.<sup>6</sup>

## Anaesthetic method

There is no recognized consensus on the best anaesthetic approach to an awake craniotomy.<sup>7</sup> This is often because the anaesthetist varies the technique dependent on the surgeon, pathology, length of surgery, and patient factors. Some neurosurgical centres have developed local practice pathways which allow selected patients to have an awake craniotomy as day surgery.

In a recent UK survey, 35% of anaesthetists reported their preferred anaesthetic approach as 'asleep-awake', 35% preferred 'asleep-awake-asleep', and the remaining 30% used an 'awake throughout' approach.<sup>6</sup>

## Sedation only 'awake throughout'

The aim of this technique is to vary the levels of sedation according to the stage of surgery whilst maintaining spontaneous ventilation without any airway device. Sedation is deepened during the application of the Mayfield Pins, skin incision, removal of the bone flap, and dura mater. It is then decreased or stopped for neurocognitive testing and mapping for resection of the lesion. The sedation can then again be increased for closure.

If the level of sedation is not titrated correctly, there are risks of airway obstruction which can lead to hypercapnia, hypoxia, and increased intracranial pressure with a 'tight' brain, or conversely a patient who is not adequately sedated will be uncomfortable and anxious.

The advantages of this technique are the avoidance of airway manipulation and its inherent risks. Some studies state that the level of sedation during the crucial stage of intra-operative cortical mapping is less and others have shown advantages in avoiding a general anaesthetic, for example, decreased nausea and vomiting.<sup>4</sup>

Currently, within the UK, the most commonly used drugs in this setting are propofol and remifentanyl target-controlled infusions. There is also some use of clonidine infusions.<sup>6</sup> Other agents that are used include benzodiazepines, droperidol, and other short-acting opioids such as fentanyl.<sup>8</sup>

Recently, dexmedetomidine has become available for use in the UK, and is routinely used in our institution. It is a highly selective  $\alpha_2$ -receptor agonist and is unique in that it provides anxiolysis and analgesia in addition to sedation without causing respiratory depression, even at very high levels. It has anaesthetic sparing properties and does not have any effect on intracranial pressure.<sup>3</sup> Patients are easily arousable despite sedation. However, it can cause hypotension and bradycardia, which are dose-dependent.<sup>3</sup>

Dexmedetomidine is usually used as a sole agent and administered intravenously. Many studies document the advantageous use of dexmedetomidine for awake craniotomies. A loading dose of 0.5–1.0  $\mu\text{g kg}^{-1}$  over 20 min is then followed by an infusion rate of 0.2–0.7  $\mu\text{g kg}^{-1} \text{h}^{-1}$  depending on the level of sedation required.<sup>9</sup>

## General anaesthetic 'asleep/awake $\pm$ asleep'

This technique involves induction of general anaesthesia and control of the airway with either a supraglottic device or intubation. When neurocognitive testing and intra-operative mapping needs to commence, the anaesthetic drugs are either reduced or stopped and the airway device is removed, when the patient has regained upper airway reflexes and it is safe to do so. Once resection of the lesion is complete, general anaesthesia can be re-introduced and with re-insertion of the airway device.

The advantages of this technique include the ability to control ventilation and therefore control carbon dioxide concentrations and prevent airway obstruction and hypoventilation. It also facilitates greater depth of anaesthesia during the painful parts of the surgery.<sup>3,7</sup>

The anaesthetic drugs used for this technique are varied, but often are the same as those used in the 'awake throughout' technique. In the UK, propofol and remifentanyl TCI are the most common, followed by the use of a volatile anaesthetic and a remifentanyl infusion.<sup>6</sup> There has been some reported use of dexmedetomidine in this technique, but usually for the awake stage of the surgery and for closure.

The airway device most often used is the standard laryngeal mask (LMA); however others seek the advantage of the gastric access and high pressure seal of the Proseal LMA<sup>TM</sup> or the integral bite block of the Supreme LMA<sup>TM</sup> or the rigidity of the iGel<sup>TM</sup>.<sup>3</sup> A minority, about 10%, of surveyed anaesthetists in the UK, opt to intubate the patient.<sup>6</sup>

Controlled ventilation is most commonly used after the airway device is inserted, with the advantages of preventing hypoventilation and hypercapnia. Neuromuscular blocking agents can be used.<sup>6</sup>

## Scalp block

Patient tolerance of an awake craniotomy relies on effective analgesia of the surgical field, and cannot rely on sedation or anaesthesia

alone, especially as these are at a minimal level during neurocognitive testing and intra-operative mapping. A scalp block also provides haemodynamic stability and decreases the stress response to painful stimuli.

Occasionally, when sedation or general anaesthesia is not used, it is the scalp block that is used as the sole technique.

Most anaesthetists will insert a bilateral scalp block before pinning of the head in Mayfield Pins. Occasionally, a scalp block is not inserted and there is a reliance on the surgeon's local anaesthetic infiltration.

The total local anaesthetic available to use with and without epinephrine must be calculated for individual patients. Studies have shown that the increase in local anaesthetic levels of levobupivacaine and ropivacaine are rapid compared with other regional blocks and similar in all patients. Despite the rapid increase of plasma levels, there were no signs of cardiovascular or central nervous system toxicity.<sup>10</sup>

The amount and type of local anaesthetic must be recorded and communicated with the surgeon as they will often supplement the scalp block with further infiltration of the skin, temporalis fascia and dura mater. The brain tissue is not painful to stimuli.

Bupivacaine, levobupivacaine, and ropivacaine of varying concentrations with and without epinephrine have been described for use in a scalp block. The addition of epinephrine, usually 1:200 000, increases the total amount of local anaesthetic that can be used, decreases localized bleeding, and maximizes the duration. However, systemic absorption may cause tachycardia and hypertension and intra-arterial injection into the superficial temporal artery is possible when blocking the auriculotemporal nerve.

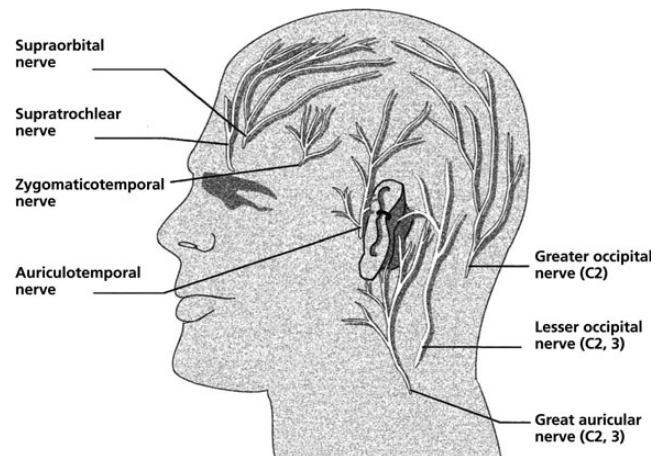
The scalp block technique includes infiltrating local anaesthetic to seven nerves on either side. This is an anatomical block, and not just a ring block. A ring block will require large volumes of local anaesthetic, increases the risk of toxicity, and will not provide anaesthesia deep to the temporalis fascia.<sup>4</sup> At the end of the scalp block; further local anaesthetic can be infiltrated locally to the pin sites.

## An approach to a scalp block<sup>3 4</sup> (Fig. 2)

This block may be inserted with the patient sedated or after the induction of anaesthesia. The skin is cleaned using either chlorhexidine or betadine. The amount inserted at each site will be dependent upon the concentration and local anaesthetic used and whether it is mixed with epinephrine. Using sterile gloves and a 23 gauge needle, the local anaesthetic is infiltrated into the following sites:

### *Supraorbital nerve, a branch of the Trigeminal nerve, V1 distribution*

It innervates the forehead, anterior part of the scalp, and top part of the head. Palpate the supraorbital notch and insert needle perpendicularly and inject.



**Fig 2** Scalp innervation. Reproduced from Costello and Cormack<sup>4</sup> with permission from Elsevier and the authors.

### *Supratrochlear nerve, a branch of the Trigeminal nerve, V1 distribution*

It innervates the forehead and anterior part of the scalp. Just medial to the supraorbital nerve injection site, above the eyebrow line, inject local anaesthetic to spread the block medially.

### *Zygomaticotemporal nerve, a branch of the Trigeminal nerve, V2 distribution*

It innervates a small area of the forehead and the temporal area. The nerve passes through the temporalis muscle to enter the temporalis fascia. Therefore, the local anaesthetic needs to be infiltrated deep and superficial to the temporalis muscle. Infiltration begins at the lateral edge of the supraorbital margin and continues to the distal aspect of the zygomatic arch.

### *Auriculotemporal nerve, a branch of the Trigeminal nerve, V3 distribution*

It innervates the temporal areas, lower lip, lower face, auricle, and the scalp above the auricle. Inject local anaesthetic about 1 cm anterior to the auricle, above the level of the temporomandibular joint. This nerve crosses over the root of the zygomatic process of the temporal bone and lies deep to the superficial temporal artery, which should be palpated to avoid intra-arterial injection.

### *Lesser occipital nerve, a branch of the second or third cervical spinal nerve*

It ascends along the posterior border of the sternocleidomastoid muscle. It innervates the scalp in the lateral area of the head posterior to the auricle. Infiltrate local anaesthetic subcutaneously behind the auricle starting from the top-down to the auricular lobule and then continue to infiltrate along the superior nuchal line to the greater occipital nerve.

### Greater occipital nerve, a branch of the second cervical spinal nerve

It arises from the first and second cervical vertebrae. It ascends to innervate the skin along the posterior part of the scalp. It can also innervate the scalp at the top of the head and over the auricle. It is located by initially palpating the occipital artery, which is found about 3–4 cm lateral to the external occipital protuberance along the superior nuchal line and then inject the local anaesthetic, medial to the occipital artery.

### Greater auricular nerve, a branch of the second and third cervical spinal nerves

It is the largest of the ascending branches and emerges around the posterior border of the sternocleidomastoid muscle. It divides into an anterior and a posterior branch and provides sensory innervation for the skin over the parotid gland and mastoid process and the auricle. Inject the local anaesthetic about 2 cm posterior to the auricle, at the level of the tragus.

## Neuropsychology/cortical mapping/resection

The patient is awoken for this stage and time is needed to allow the patient to adjust to the environment to ensure that they are ready for clinical evaluation.

A calm, quiet environment is required for patient awakening. It is upon emergence that several complications can occur, for example, pain from either the pins or discomfort from the prolonged immobility, agitation or nausea, and vomiting. It is important to address these issues quickly and effectively as it can lead to poor surgical conditions.

Cortical stimulation, also known as cortical or brain mapping, aims to localize the eloquent areas of the brain through direct electrical stimulation of the cerebral cortex by electrodes. These areas are those involved in speech, language, and motor abilities. Specifically, the Broca's area is needed for speech production and language processing and the Wernicke's area is used for language comprehension. It is also important to identify the motor and sensory cortex.<sup>3</sup> Any alteration of speech, language, and motor function by stimulation is communicated to the surgeon.<sup>8</sup> Resection takes place only after the cortex has been functionally mapped by this process.

### Adverse incidents

Seizures, either focal or generalized, are most likely to occur during cortical mapping. They are treated by irrigating the brain tissue with ice-cold saline. They usually cease with this treatment alone, but occasionally benzodiazepines, anti-epileptic drugs, or re-sedation with airway control are required.

An emergency plan for airway control has to be in place at all times and this can be challenging as the patient's head is fixed in head pins and often away from the ventilator. The options include

**Table 2** Intra-operative adverse incidents

Airway/respiratory compromise
Hypoventilation/airway obstruction/apnoea
Hypoxia
Hypercapnia
Failure of airway device, for example LMA
Conversion to GA
Pulmonary aspiration
Cardiovascular
Hypotension/hypertension
Bradycardia/tachycardia
Anaesthetic technique
Inadequate or excessive sedation
Pain or discomfort—often because of positioning
Nausea, vomiting, or both
Local anaesthetic toxicity
Surgical factors
Focal seizures, generalized seizures, or both
Venous air embolism
Focal neurological deficit
Brain swelling ('tight' brain)
Mental/psychological factors
Anxiety/agitation/intolerance of the procedure
Patient tiredness/fatigue
Revoking consent for the procedure

the insertion of an LMA which may be easier than oro-tracheal intubation.

Awake craniotomy is generally a well-tolerated procedure with a low rate of conversion to general anaesthesia and a low rate of complications. One of the most frequent complications is patient intolerance of the procedure, often because of the urinary catheter or prolonged positioning and intra-operative seizures.<sup>3 6</sup> Table 2 lists intra-operative adverse incidents.

### Closure

Once resection is completed, the patient can be re-sedated or re-anaesthetized with re-insertion of the airway device, even if in the lateral position. Closure of the dura mater, the bone flap, and the scalp are then performed, the pins removed and the patient woken up. If remifentanyl has been used, it can be run at low infusion rates to aid a 'smooth' wake-up and avoidance of coughing.

### Postoperative

Following an awake craniotomy the patient returns to either a neurosurgical ward or a high-dependency unit bed.<sup>6</sup> It is imperative that close neurological monitoring continues as postoperative haematomas can develop, especially in the first 6 h after operating. This may require an urgent repeat craniotomy for evacuation of the clot.

Some neurosurgical centres, including within the UK, carefully select appropriate patients for day case awake craniotomy surgery. There are stringent inclusion and exclusion criteria and the use of routine postoperative imaging for haematomas and access to advice after discharge if needed. Most patients are in hospital for 1–2 days after operation.

After the scalp block has worn off, systemic pain relief is used. The use of postoperative pain relief can be decreased in patients who have received a scalp block. Regular paracetamol and opioids, such as codeine, morphine, or oxycodone, are used.

## Future developments

There is increasing evidence that an awake craniotomy would be an appropriate choice for removal of all supratentorial tumours non-selectively. It can maximize lesion resection, which can be linked to improved survival rates, and has low complication rates.<sup>7 11</sup>

The development of techniques that allow functional brain mapping are rapidly developing and may supersede the awake craniotomy. For example intra-operative magnetic resonance (MR) scanners are currently in use in some neurosurgical centres. In development are new technologies that will enable preoperative brain mapping and these may have significant role in the future.<sup>3 4 12</sup>

## References

1. Yordanova YN, Moritz-Gasser S, Duffau H. Awake surgery for WHO grade II gliomas within 'noneloquent' areas in the left dominant hemisphere: toward a 'supratotal' resection. *J Neurosurg* 2011; **115**: 232–239
2. July J, Manninen P, Lai J, Yao Z, Bernstein M. The history of awake craniotomy for brain tumor and its spread into Asia. *Surg Neurol* 2009; **71**: 621–5
3. Brydges G, Atkinson R, Perry MJ, Hurst D, Laqua T, Wiemers J. Awake craniotomy: a practice overview. *AANA J* 2012; **80**: 61–8
4. Costello TG, Cormack JR. Anaesthesia for awake craniotomy: a modern approach. *J Clin Neurosci* 2004; **11**: 16–9
5. Sinha PK, Koshy T, Gayatri P, Smitha V, Abraham M, Rathod RC. Anaesthesia for awake craniotomy: a retrospective study. *Neurol India* 2007; **55**: 376–81
6. Burnand C, Sebastian J. Survey of anaesthesia for awake craniotomy. *J Neurosurg Anesthesiol* 2012; **24**: 249
7. Sarang A, Dinsmore J. Anaesthesia for awake craniotomy – evolution of a technique that facilitates awake neurological testing. *Br J Anaesth* 2003; **90**: 161–5
8. Pereira LCM, Olivira KM, L'Abbate GL, Sugai R, Ferreira JA, da Motta LA. Outcome of fully awake craniotomy for lesions near the eloquent cortex: analysis of a prospective surgical series of 79 supratentorial primary brain tumors with long follow-up. *Acta Neurochir* 2009; **151**: 1215–30
9. Ard JL, Jr, Bekker AY, Doyle WK. Dexmedetomidine in awake craniotomy: a technical note. *Surg Neurol* 2005; **63**: 114–17
10. Costello TG, Cormack JR, Mather LE, LaFerlita B, Murphy MA, Harris K. Plasma levobupivacaine concentrations following scalp block in patients undergoing awake craniotomy. *Br J Anaesth* 2005; **94**: 848–51
11. Serletis D, Bernstein M. Prospective study of awake craniotomy used routinely and nonselectively for supratentorial tumors. *J Neurosurg* 2007; **107**: 1–6
12. Wrede KH, Stieglitz LH, Fiferina A et al. Patient acceptance of awake craniotomy. *Clin Neurol Neurosurg* 2011; **113**: 880–84

Please see multiple choice questions 5–8.